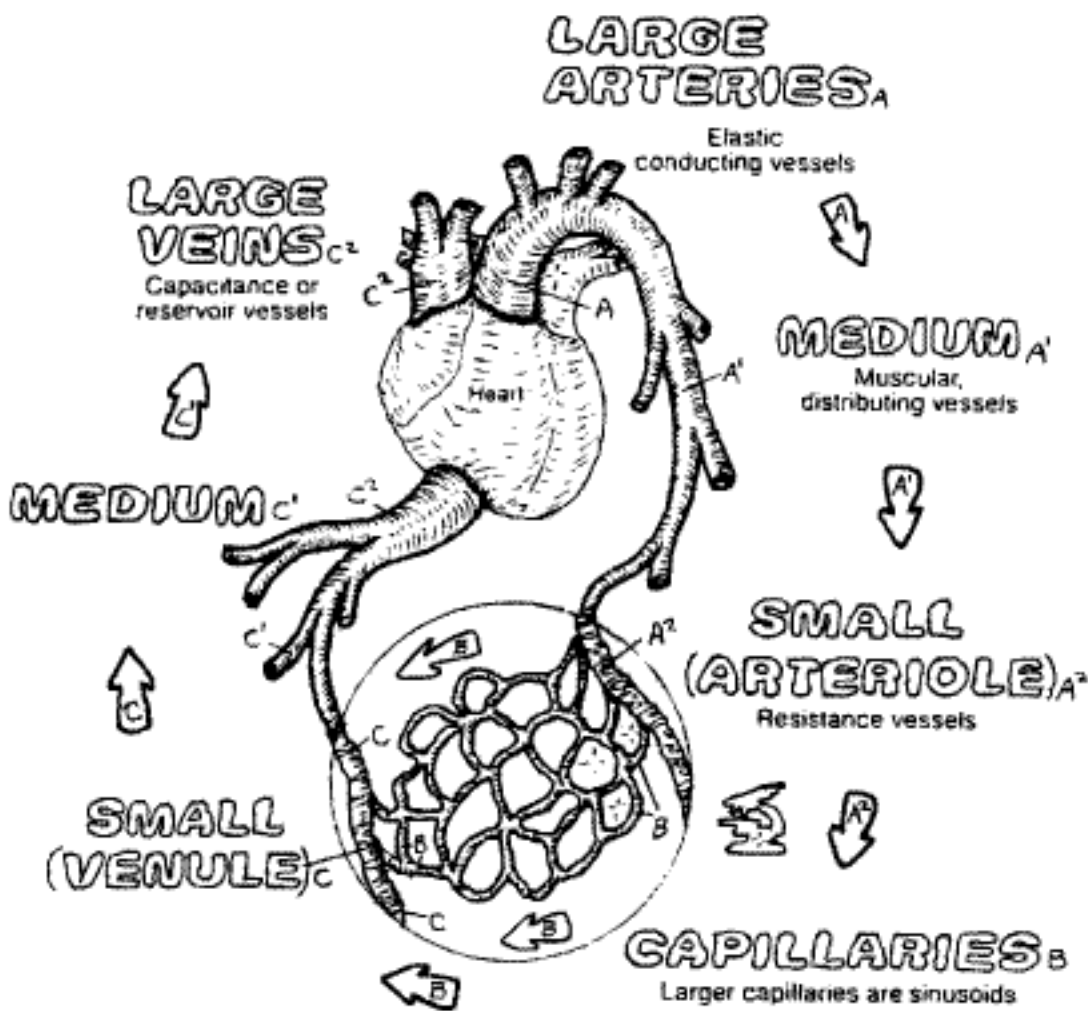


CARDIOVASCULAR SYSTEM
BLOOD VESSELS



VESSEL STRUCTURE*

- TUNICA INTERNA:**
 ENDOTHELIUM,
 INTERNAL ELASTIC LAMINA^E
- TUNICA MEDIA:**
 SMOOTH MUSCLE^F
 EXTERNAL ELASTIC LAMINA.
- TUNICA EXTERNA:**
 FIBROUS TISSUE^H

