Color and label the parts of the hip (coxal) bone:

1. O ilium
   a. iliac crest
   b. anterior superior iliac spine
   c. posterior superior iliac spine
2. O pubis
   a. superior ramus (of pubis)
   b. pubic tubercle
   c. inferior ramus (of pubis)
3. O ischium
   a. spine (of ischium)
   b. ramus (of ischium)
   c. ischial tuberosity
4. O symphysis pubis

Color and label:

5. O sacrum
6. O femur
   a. head of femur
   b. neck of femur
   c. greater trochanter
   d. lesser trochanter
   e. linea aspera
   f. lateral epicondyle
   g. lateral condyle
   h. medial epicondyle
   i. medial condyle
   j. intercondylar fossa
7. O patella
8. O tibia
   a. tibial tuberosity
   b. medial malleolus
9. O fibula
   a. head of fibula
   b. lateral malleolus
10. O tarsals
    a. talus
    b. calcaneous
11. O metatarsals
12. O phalanges

Label:

13. acetabulum
14. obturator foramen
15. greater sciatic notch
16. true pelvis

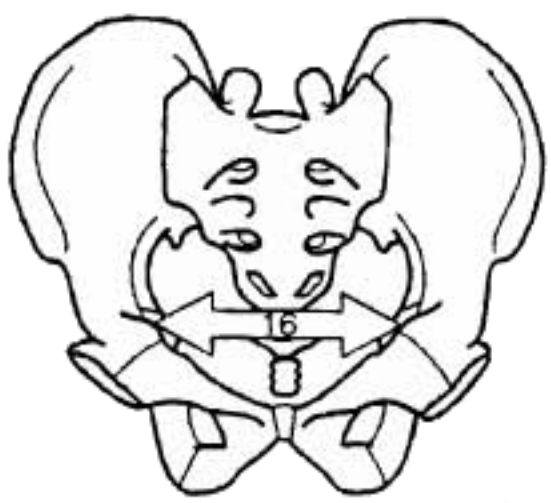

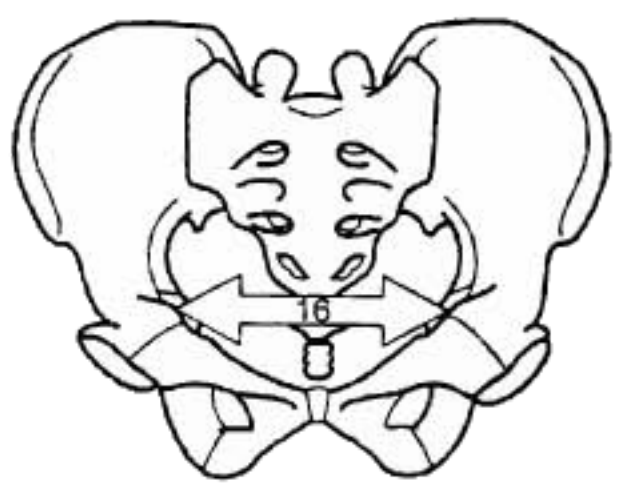

Figure 6.12c. Male vs. female pelvis.

Exercise 6.12:

1. Which bones correspond to the following surface structures?

_____ a. thigh _____ c. lower leg

_____ b. hip _____ d. heel

_____ 2. What bones make up the pelvic girdle?

_____ 3. What type of cartilage is the symphysis pubis? What advantage does this type of cartilage offer? (see tissues, p. 44)

_____ 4. You sit on your _____ .

_____ 5. When you put your hands on your hips you are touching the _____ .

_____ 6. Embryologically, the ischium, ilium, and pubis are separate bones. Are they separate in the adult?

_____ 7. Is the tibia lateral or medial to the fibula?

_____ 8. The fibula articulates with the _____ .

_____ 9. The bump on the lateral surface of the ankle is the _____ of the _____ (bone).

_____ 10. The bump on the medial surface of the ankle is the _____ of the _____ (bone).

_____ 11. The tibia articulates with which tarsal?

_____ 12. How many phalanges make up the big toe? the other toes?

_____ 13. Which is wider—the male or female pelvis?

_____ 14. Is the male or female pelvis deeper?